

# Role of alloplastic reconstruction of the temporomandibular joint in the juvenile idiopathic arthritis population

B.L. Hechler<sup>a,\*</sup>, N.S. Matthews<sup>b</sup>

<sup>a</sup> Department of Surgery - Division of Plastic, Maxillofacial, and Oral Surgery, and Department of Head and Neck Surgery & Communication Sciences - Duke University Medical Center, 2301 Erwin Road, Durham, NC 27703

<sup>b</sup> Department of Oral & Maxillofacial Surgery – University of North Carolina Hospitals, UNC School of Dentistry, Campus Box 7450, Chapel Hill, NC 27599

Accepted 27 June 2020

Available online 13 July 2020

## Abstract

We present outcomes following total joint replacement of the temporomandibular joint (TMJ) in adolescent and young adult patients with juvenile idiopathic arthritis (JIA), and discuss a multidisciplinary treatment model. A retrospective review was performed of patients presenting to the University of North Carolina Oral and Maxillofacial Surgery Service (Chapel Hill, NC) from 2016–2018 who underwent unilateral or bilateral total replacement of the TMJ for a diagnosis of end-stage joint disease secondary to JIA. Inclusion criteria included diagnosis by a rheumatologist, presentation to our department in adolescence (under 18 years of age), surgical intervention in adolescence or young adulthood (under 25 years of age), and documentation of preoperative and postoperative pain, maximum incisal opening (MIO), and quality of life measures. A database was created and data were then analysed both qualitatively and quantitatively. Five patients met the inclusion criteria. All achieved MIO of more than 35 mm with a mean improvement of 24 mm, and were able to tolerate a regular diet. All preoperative pain had essentially been eliminated. All patients reported a considerable improvement in quality of life. To our knowledge, this is the first report to document a series of paediatric and young adult patients with JIA who required total replacement of the joint for end-stage joint disease. To our knowledge, it is also the first to describe the use of a collaborative clinic of oral and maxillofacial surgeons, neuroradiologists, dental radiologists, orofacial pain specialists, paediatric rheumatologists, and paediatric nurse practitioners, to care for these patients.

© 2020 The British Association of Oral and Maxillofacial Surgeons. Published by Elsevier Ltd. All rights reserved.

**Keywords:** TMJ; juvenile idiopathic arthritis; joint replacement

## Introduction

Juvenile idiopathic arthritis (JIA) is a rheumatological disease that is diagnosed before the age of 16, with 17%–87% of patients eventually exhibiting some degree of temporomandibular joint (TMJ) disease. Joints in affected patients often show progressive bony erosion and loss of joint space, with intermittent periods of acute synovitis and/or effusion.

Eventually, they demonstrate obliteration of the articular disc and restrictive heterotopic calcification. There is currently a paucity of studies describing total joint replacement in paediatric JIA patients, with most reports being single case reports or case series that include patients over the age of 30.<sup>1–4</sup>

The purpose of this study was to describe our experience of treating end-stage TMJ disease in paediatric and young adult patients with JIA by customised total joint replacement, and to report the outcomes of the procedure. In addition, we have highlighted our integrated treatment model, which involves a monthly collaborative clinic with multiple disciplines including oral and maxillofacial, and

\* Corresponding author at: Duke University Medical Center, 2301 Erwin Road, Durham, NC 27703. Tel.: +1 919 660 0311; Fax: +1 919 813 6367.

E-mail address: [Benjamin.Hechler@duke.edu](mailto:Benjamin.Hechler@duke.edu) (B.L. Hechler).

paediatric rheumatology providers. All surgeries were performed using custom joints from the TMJ Concepts system (TMJ Concepts).

## Patients and methods

A retrospective review was performed of patients who presented to the University of North Carolina Oral and Maxillofacial Surgery Service (Chapel Hill, NC) from 2016 – 2018, and who underwent unilateral or bilateral alloplastic total joint replacement for end-stage joint disease secondary to JIA. Inclusion criteria included diagnosis secured by a rheumatologist, presentation to our department in adolescence (under 18 years of age), surgical intervention in adolescence or young adulthood (under 25 years of age), as well as complete documentation of preoperative and postoperative pain measured on a visual analogue scale, and maximum incisal opening (MIO). Exclusion criteria included no formal diagnosis of JIA, no need for total joint replacement before the age of 25, or incomplete documentation. Five patients met the inclusion criteria. A database was created consisting of each patient's age at presentation, chief complaint, age at surgery, pain, MIO, and subjective quality of life at each visit. The data were analysed both qualitatively and quantitatively.

The study was approved by the institutional review board at the University of North Carolina Hospitals (Chapel Hill, NC; IRB number 19-1974).

## Results

### Case 1

A 17-year-old female was referred to our department by her rheumatologist with a diagnosis of polyarticular JIA that had previously been treated with methotrexate. She was on no medications at the time of referral. Her chief complaint was limited mouth opening, subjective joint “stiffness”, and baseline TMJ pain of 2/10 with maximum jaw pain of 7/10 on function. Her initial physical examination revealed MIO of 52 mm, mild tenderness of the bilateral TMJ, and bilateral TMJ clicks on opening and closing. Initial magnetic resonance imaging (MRI) revealed small effusions bilaterally.

She underwent multiple triamcinolone/bupivacaine TMJ injections, jaw physiotherapy, systemic treatment with methotrexate, etanercept (later abatacept), and eventually adalimumab. Her pain continued, MIO deteriorated to 20 mm with severely restricted excursive movements of no more than 1 mm in all directions, and she developed 3-4 mm of apertognathia. Repeat MRI revealed advanced inflammatory arthrosis of the bilateral TMJ with evidence of right TMJ ankylosis (Fig. 1).

She subsequently underwent orthodontic treatment in combination with bilateral alloplastic total joint replacement.

At the most recent follow up (29 months), she had no pain and could tolerate a normal diet. MIO was 48 mm (Fig. 2).

### Case 2

A 9-year-old female was referred to our department by her rheumatologist with a diagnosis of polyarticular JIA. She was currently undergoing methotrexate and etanercept therapy. Her chief complaint was limited mouth opening, with baseline TMJ pain of 2/10 and maximum jaw pain of 4/10 on function. Her initial physical examination revealed MIO of 38 mm and mild tenderness of the bilateral TMJ. Initial MRI revealed condylar flattening and erosive changes bilaterally with right intrameniscal signal degeneration.

She underwent a single round of triamcinolone/bupivacaine TMJ injections and continued systemic treatment with methotrexate and etanercept. Her pain continued and MIO deteriorated to 18 mm. Repeat MRI revealed no bilateral TMJ translation on opening with appreciable right pannus formation and heterotopic ossification. She subsequently underwent right alloplastic total joint replacement. At the most recent follow up (14 months) she had no pain on the operated side and could tolerate a normal diet. MIO was 36 mm.

### Case 3

A 13-year-old male was referred to our department by his rheumatologist with a diagnosis of oligoarticular JIA that was being treated with methotrexate. His chief complaint was limited MIO, subjective joint stiffness, and baseline TMJ pain (worse in the right than the left) with maximum jaw pain of 7/10 on function. His initial physical examination revealed MIO of 55 mm, mild-moderate tenderness to the bilateral TMJ, and bilateral TMJ clicks on opening. Initial MRI revealed condylar flattening and erosive changes bilaterally with synovial thickening that was greater on the right than on the left.

He underwent a single round of triamcinolone/bupivacaine TMJ injections, had jaw physiotherapy, and continued systemic treatment with methotrexate. His pain continued and MIO deteriorated to 18 mm with severely restricted excursive movements of no more than 1 mm in all directions. A computed tomogram (CT) revealed bilateral severely reduced joint spaces, as well as pericondylar bony curtains descending from the skull base to encase the condylar heads (Fig. 3).

He subsequently underwent bilateral alloplastic total joint replacement and a sliding genioplasty camouflage procedure. At the most recent follow up (20 months) he had no pain and could tolerate a normal diet. MIO was 48 mm (Figs. 4 and 5).

### Case 4

A 12-year-old female was referred to our department by her rheumatologist with a diagnosis of oligoarticular JIA that

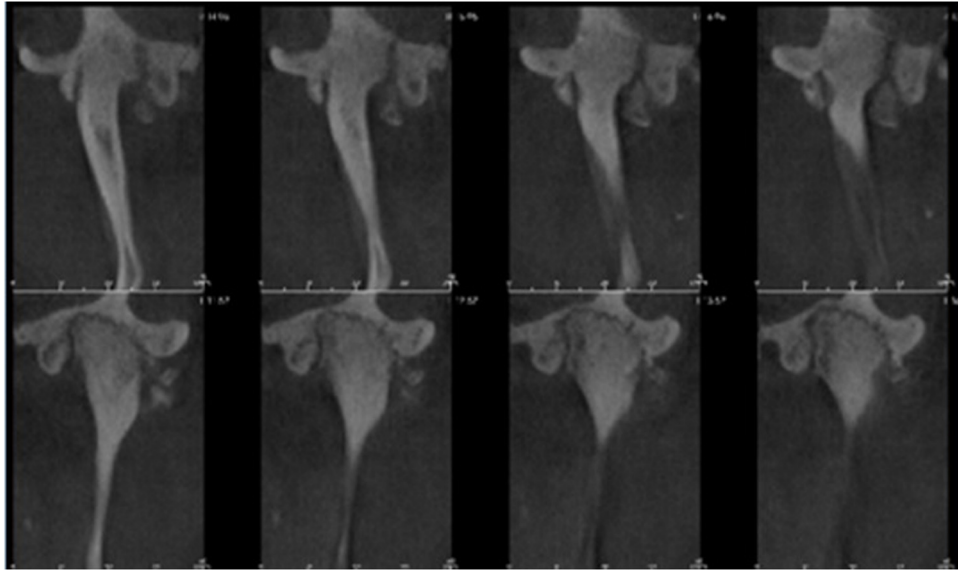


Fig. 1. Case 1: coronal cuts through the right (upper row) and left (lower row) temporomandibular joints demonstrating significant bilateral pericondylar heterotopic bone formation and complete bony ankylosis on the right.

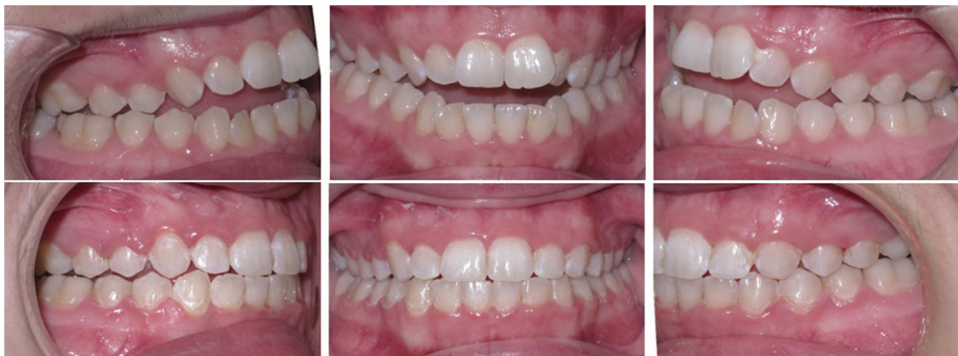

Fig. 2. Case 1: preoperative (upper row) and postoperative (lower row) occlusion including perioperative orthodontic treatment.

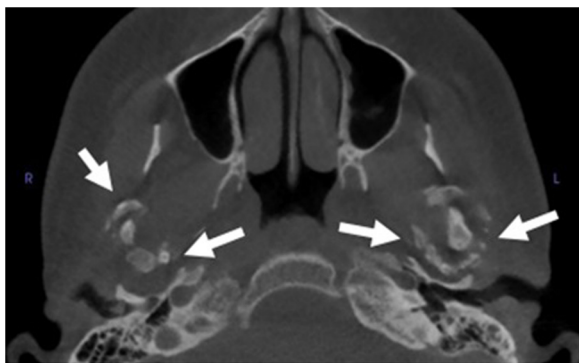

Fig. 3. Case 3: axial cut through the right and left temporomandibular joints demonstrating appreciable bilateral pericondylar heterotopic bone formation (white arrows).

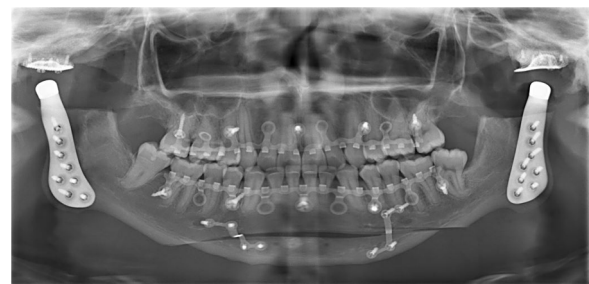

Fig. 4. Case 3: postoperative panoramic radiograph.

was being treated with methotrexate. Her chief complaint was occasional mild to moderate pain in the left TMJ with intermittent open lock. She denied baseline TMJ pain. Her initial physical examination revealed MIO of 42 mm and

was otherwise normal. Initial MRI revealed bilateral anterior disc displacement with moderate effusions, and the left disc appeared buckled and irregular.

She underwent multiple triamcinolone/bupivacaine TMJ injections and systemic treatment with methotrexate and later etanercept. Her pain continued and MIO deteriorated to 25 mm. MRI and CT revealed complete erosion of the right condyle and severe erosion of the left with contact between

the condyle and glenoid fossa on both sides. Pericondylar heterotopic ossification could be seen descending from the skull base to encase the condylar heads.

She subsequently underwent bilateral total joint replacement and a sliding camouflage genioplasty procedure. At the most recent follow up (14 months) she had minimal pain and could tolerate a normal diet. MIO was 45 mm.

### Case 5

A 16-year-old female was referred to our department by her rheumatologist with a diagnosis of oligoarticular JIA that was currently being treated with methotrexate. Her chief complaint was a “grinding” sensation in her TMJ, with baseline TMJ pain of 1/10 and maximum jaw pain of 5/10 on function. Her initial physical examination revealed MIO of 46 mm and TMJ crepitus that was greater in the right than in the left. Initial MRI revealed severe condylar erosion that was greater in the right than the left, bilateral synovitis, and bilateral anterior disc displacement with maceration of the right disc.

She underwent multiple rounds of triamcinolone/bupivacaine TMJ injections, and had targeted splint therapy for parafunctional habits. She continued systemic treatment with methotrexate and later with leflunomide. Her pain continued and MIO deteriorated to 28 mm with severely restricted excursive movements of no more than 1–3 mm in all directions. Repeat MRI revealed new heterotopic bone formation surrounding the condylar head in the left TMJ.

She subsequently underwent bilateral total joint replacement. At the most recent follow up (10 months), she had no pain and could tolerate a normal diet. MIO was 50 mm.

### Discussion

JIA is a rheumatological disease that is diagnosed before the age of 16, and 17% - 87% of these patients eventually exhibit some degree of TMJ disease.<sup>5</sup> In affected patients these joints often show progressive bony erosion, loss of joint space, intermittent periods of acute synovitis and/or effusion, and eventual restrictive heterotopic calcification. Our series of patients had total joint replacements at a young age.

Practice patterns in the treatment of TMJ disease in the JIA population have varied widely. Guidelines have been put forth regarding what should be considered the “bare minimum” for clinical examination,<sup>6</sup> yet we know that clinical examination in this group not only often falls short but is frequently misleading.<sup>7,8</sup> Controversy remains about whether intra-articular corticosteroid injection has a role in early TMJ inflammatory disease,<sup>9,10</sup> although as total joint replacement becomes more routine, its predictable result in the management of end-stage disease is becoming a near unanimous standard. Although guidelines for total replacements have yet to be created in the United States, they do exist elsewhere.<sup>11</sup>

As a solution to the uncertainty regarding monitoring and treatment in early-stage JIA, we have developed a collaborative, multidisciplinary clinic model between the following specialties at the University of North Carolina – Chapel Hill, NC, and Duke University – Durham, NC: oral and maxillofacial surgery, neuroradiology, dental radiology, orofacial pain, paediatric rheumatology, and paediatric nurse practitioners.

This monthly clinic model involves a “virtual” morning clinic during which patients’ imaging and progress notes are reviewed and initial treatment planning is collaboratively determined. The “virtual” clinic utilises Health Insurance Portability and Accountability Act (HIPAA)-compliant Zoom teleconferencing software to facilitate communication with all remote participating clinicians. The morning clinic is then followed by a “real-time” afternoon clinic when patients are seen face-to-face and treatment plans are finalised. This focused collaboration amongst specialties has streamlined our ability to confidently determine the best treatment options for individual patients, given that there is no consistent algorithm for the successful treatment of this complex population. In addition, the opportunity for the patient and their family to meet a team of providers, each dedicated to different aspects of their treatment, not only builds the patient’s trust and confidence, but expedites therapeutic interventions. In summary, this multidisciplinary clinic model, which lies at the interface of interprofessional collaboration and telehealth, is cost-effective, time-saving, and provides a consensus view of the patient’s treatment. It also allows us to better understand the patient’s disease process and the rationale for the chosen treatment.

What is universally seen in our young patients with end-stage TMJ disease is a pericondylar curtain of heterotopic bone descending from the skull base to the condylar neck. Although this is often appreciated on routine panoramic imaging, the presentation is impressive on 3-dimensional radiography, and it is well-documented that chronic inflammation is a risk factor for heterotopic bone formation.<sup>12</sup> It is unclear whether this presentation is part of the disease process itself in a subset of JIA patients, but the possibility of intra-articular corticosteroid injection leading to intrajoint or periarticular heterotopic bone formation, including around peripheral extremity joints, has been highlighted in the rheumatological literature.<sup>13,14</sup>

Multiple studies have specifically reported on the presence of heterotopic bone formation in JIA patients who have intra-articular corticosteroid injections (IACS), but a cause-and-effect relation has never been proven.<sup>15,16</sup> More recently, Stoll et al retrospectively reviewed their experience with JIA patients and IACS.<sup>17</sup> Their results illustrate the complexity of the cause-and-effect relation, as they found that the total number of these injections and time-to-first injection were associated with an increased risk of heterotopic bone formation, yet they noted that children with more severe arthritis were more likely to receive IACS.

We acknowledge the inherent concerns regarding the effects on facial growth and development of surgical inter-



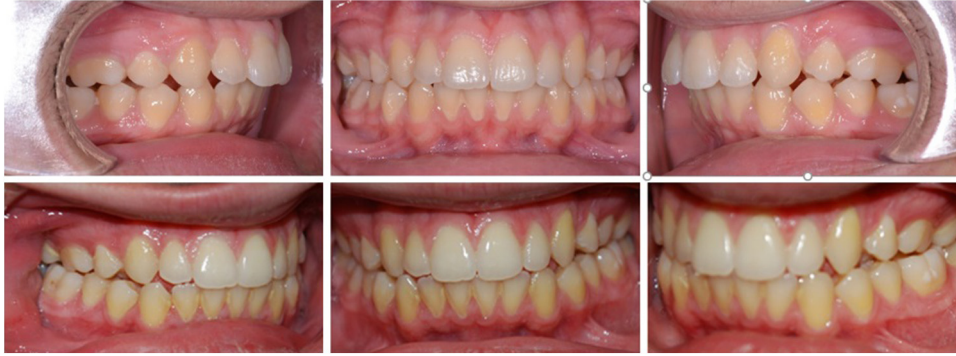

Fig. 5. Case 3: preoperative (upper row) and postoperative (lower row) occlusion. The patient refused orthodontic treatment.

ventions that involve alloplastic implants in the paediatric and young adult population. Indeed, these same concerns related to IACS injections have been raised in this group. Traditionally, neurocranial growth—including the lateral temporal bone, glenoid fossa, and eminence—is considered to be 95% complete by approximately 10 years of age. The sphenoccipital synchondrosis typically begins to fuse in early adolescence (12–15 years of age), and at this time maxillary and zygomatic growth has also nearly ceased.<sup>18</sup> With regards to growth, there are three questions that we wish to address:

- 1 How does condylectomy affect mandibular growth in the healthy patient?
- 2 How does condylectomy affect mandibular growth in the JIA patient?
- 3 How does alloplastic joint replacement compare with costochondral graft reconstruction?

First, although it is well known that bony TMJ ankylosis in childhood can result in restricted mandibular growth, it seems less well known that condylectomy does not result in the cessation of growth. Indeed, both animal and human studies have shown not only that the condyle can reform, but that mandibular growth can continue (assuming a stable glenoid fossa relation has been established).<sup>19–22</sup> Therefore, at the most basic level, the loss of condylar tissue in the growing patient does not result in the cessation of mandibular growth.

Secondly, the concern as to whether gap arthroplasty and alloplastic repair have a negative impact on mandibular growth is a moot point in the treatment of the JIA patient, whose disease process is defined by a decelerated, backward-rotating growth pattern.<sup>23</sup> In JIA, active TMJ involvement resulting in end-stage disease—the very indication for joint replacement in these patients—is at times defined by a shortening of the ramus. It is therefore not the resection or reconstruction, but the untreated disease process, that is detrimental to growth.

Thirdly, although in theory, an autogenous reconstructive option with the potential for growth (such as a costochondral graft) is appealing, in practice this not only involves a second surgical site with associated morbidity, but also (given the patient's underlying inflammatory TMJ arthritis)

Table 1

Summary of preoperative and postoperative maximum incisal opening (MIO) and pain scores.

Case No.	MIO (mm)		Pain	
	Preoperative	Postoperative	Preoperative	Postoperative
1	20	48 (29 months)	3/10 to 7/10	0/10
2	18	36 (14 months)	2/10 to 4/10	1/10
3	18	48 (20 months)	0/10 to 7/10	0/10
4	25	45 (14 months)	1/10 to 7/10	0/10
5	28	50 (10 months)	1/10 to 5/10	0/10

an unpredictable risk of re-ankylosis.<sup>24</sup> Mercuri provided an excellent comparison of alloplastic total joint replacements and costochondral grafts in TMJ reconstruction,<sup>25</sup> and many others have documented the increased risk of re-ankylosis in inflammatory conditions, as well as the fact that desired, symmetrical growth is achieved only in the minority of cases.<sup>26–28</sup> We have therefore adopted a thoughtful, multidisciplinary team approach that balances the detrimental growth effects of the disease process itself—and possibly of IACS injections—with that of definitive total replacement.

Our cohort of patients has responded remarkably well to date (Table 1). Furthermore, all have reported considerable improvements in overall quality of life, particularly with regards to eating in social situations. Long-term follow up will shed light on the stability of these early postoperative results, particularly in this relatively young population. Six-monthly to yearly clinical and radiographic reassessment of TMJ pain, function, and craniofacial growth is being undertaken for all patients in this cohort until skeletal maturity has been achieved. Minor alterations in occlusion will be the most sensitive method of detecting any continued postoperative growth.

It should be noted that while preoperative orthodontic preparation was offered to all of our patients, only one (Case 1) opted to proceed. This highlights the severe effects that JIA affecting the TMJ can have on quality of life, with pain, limited MIO, and psychosocial impact being of such concern that patients often wish to proceed with joint replacements as soon as possible. In this complex clinical setting, we have found that the sliding camouflage augmentation genioplasty proce-

dure helps total replacement to achieve one of the patient's goals - that of an improved facial appearance and profile - as quickly as possible.

Our outcomes are consistent with recent reports from other institutions that use the TMJ Concepts system in non-JIA patients. Sidebottom and Gruber, in their report of 74 patients who had custom joint replacements, showed a mean improvement in MIO of 11.3 mm, improvement in pain on a 100-point visual analogue scale (VAS) from 72 to 8, and an improvement in tolerated dietary consistency on a 100-point VAS from 38 to 93. They also showed that 96% of patients reported a better quality of life postoperatively.<sup>29</sup> Similarly, Burgess et al reported on 42 patients who received custom joint replacements, showing a mean MIO improvement of 17.3 mm and a mean improvement in pain of 6.6 on a 10-point VAS. They also showed that 90% of patients reported a better quality of life.<sup>30</sup>

## Conclusion

To our knowledge, this is the first report to document a series of exclusively paediatric and young adult patients with JIA who required total replacement of the TMJ for end-stage joint disease. It is also the first report that describes the use of a collaborative clinic between six specialties to care for them. We believe that the favourable postoperative outcomes we have experienced thus far can, in part, be directly attributed to the investment that our patients feel they have in their own care, given the breadth of attention that they receive preoperatively and postoperatively through this collaborative clinic.

## Conflict of interest

We have no conflicts of interest.

## Ethics statement/confirmation of patients' permission

This study was approved by the institutional review board at the University of North Carolina Hospitals (Chapel Hill, NC; IRB number 19-1974). None required; IRB approved.

## References

1. Fanaras N, Parry NS, Matthews NS. Multidisciplinary approach in the management of absolute trismus with bilateral temporomandibular joint replacements for a patient with juvenile idiopathic arthritis. *J Oral Maxillofac Surg* 2014;**72**:2262–72.
2. Stoor P, Hodzic Z, Arte S. Surgical treatment of dentofacial deformities caused by juvenile idiopathic arthritis. *J Craniofac Surg* 2018;**29**:e51–7.
3. Webster K, McIntyre G, Laverick S, et al. Treatment of class 2 skeletal malocclusion with degenerative arthritis of the condyles using custom-made temporomandibular joint replacements and genioplasty. *J Orthod* 2017;**44**:55–8.
4. Haq J, Patel N, Weimer K, et al. Single stage treatment of ankylosis of the temporomandibular joint using patient-specific total joint replacement and virtual surgical planning. *Br J Oral Maxillofac Surg* 2014;**52**:350–5.
5. Te Veldhuis EC, Te Veldhuis AH, Koudstaal MJ. Treatment management of children with juvenile idiopathic arthritis with temporomandibular joint involvement: a systematic review. *Oral Surg Oral Med Oral Pathol Oral Radiol* 2014;**117**:581–9.
6. Stoustrup P, Twilt M, Spiegel L, et al. Clinical orofacial examination in juvenile idiopathic arthritis: international consensus-based recommendations for monitoring patients in clinical practice and research studies. *J Rheumatol* 2017;**44**:326–33.
7. Weiss PF, Arabashi B, Johnson A, et al. High prevalence of temporomandibular joint arthritis at disease onset in children with juvenile idiopathic arthritis, as detected by magnetic resonance imaging but not by ultrasound. *Arthritis Rheum* 2008;**58**:1189–96.
8. Melchiorre D, Falcini F, Kaloudi O, et al. Sonographic evaluation of the temporomandibular joints in juvenile idiopathic arthritis. *J Ultrasound* 2010;**13**:34–7.
9. Kinard BE, Abramowicz S. Juvenile idiopathic arthritis practice patterns among oral and maxillofacial surgeons. *J Oral Maxillofac Surg* 2017;**75**:2333.e1–8.
10. Antonarakis GS, Courvoisier DS, Hanquinet S, et al. Benefit of temporomandibular joint lavage with intra-articular steroids versus lavage alone in the management of temporomandibular joint involvement in juvenile idiopathic arthritis. *J Oral Maxillofac Surg* 2018;**76**:1200–6.
11. Sidebottom AJ, UK Replacement Surgeons, British Association of Oral and Maxillofacial Surgeons. Guidelines for the replacement of temporomandibular joints in the United Kingdom. *Br J Oral Maxillofac Surg* 2008;**46**:146–7.
12. Mercuri LG, Saltzman BM. Acquired heterotopic ossification of the temporomandibular joint. *Int J Oral Maxillofac Surg* 2017;**46**:1562–8.
13. Job-Deslandre C, Menkes CJ. Complications of intra-articular injections of triamcinolone hexacetonide in chronic arthritis in children. *Clin Exp Rheumatol* 1990;**8**:413–6.
14. Sparling M, Malleson P, Wood B, et al. Radiographic followup of joints injected with triamcinolone hexacetonide for the management of childhood arthritis. *Arthritis Rheum* 1990;**33**:821–6.
15. Ringold S, Thapa M, Shaw EA, et al. Heterotopic ossification of the temporomandibular joint in juvenile idiopathic arthritis. *J Rheumatol* 2011;**38**:1423–8.
16. Lochbühler N, Saurenmann RK, Müller L, et al. Magnetic resonance imaging assessment of temporomandibular joint involvement and mandibular growth following corticosteroid injection in juvenile idiopathic arthritis. *J Rheumatol* 2015;**42**:1514–22.
17. Stoll ML, Amin D, Powell KK, et al. Risk factors for intraarticular heterotopic bone formation in the temporomandibular joint in juvenile idiopathic arthritis. *J Rheumatol* 2018;**45**:1301–7.
18. Sperber GH. *Craniofacial embryology (dental practical handbooks)*. Butterworth - Heinemann; 1989.
19. Adler EA. Early condylectomy to prevent prognathism: a preliminary report. *J Oral Surg* 1976;**34**:702–6.
20. Lovasko JH, Laskin DM. Facial growth after condylectomy and alloplastic condylar replacement. *J Oral Surg* 1978;**36**:685–92.
21. Miyamoto K, Vickers R, Ishimaru JI, et al. Effect of unilateral condylectomy on the sheep temporomandibular joint. *Br J Oral Maxillofac Surg* 1999;**37**:401–4.
22. Miyamoto K, Matsuura H, Jones RH, et al. Unilateral mandibular condylectomy in lambs. *Br J Oral Maxillofac Surg* 2001;**39**:304–9.
23. Kjellberg H. Craniofacial growth in juvenile chronic arthritis. *Acta Odontol Scand* 1998;**56**:360–5.
24. Movahed R, Mercuri LG. Management of temporomandibular joint ankylosis. *Oral Maxillofac Surg Clin North Am* 2015;**27**:27–35.
25. Mercuri LG. Costochondral graft versus total alloplastic joint for temporomandibular joint reconstruction. *Oral Maxillofac Surg Clin North Am* 2018;**30**:335–42.

26. Guyuron B, Lasa Jr CI. Unpredictable growth pattern of costochondral graft. *Plast Reconstr Surg* 1992;**90**:880–6.
27. Svensson B, Adell R. Costochondral grafts to replace mandibular condyles in juvenile chronic arthritis patients: long-term effects on facial growth. *J Craniomaxillofac Surg* 1998;**26**:275–85.
28. Ross RB. Costochondral grafts replacing the mandibular condyle. *Cleft Palate Craniofac J* 1999;**36**:334–9.
29. Sidebottom AJ, Gruber E. One-year prospective outcome analysis and complications following total replacement of the temporomandibular joint with the TMJ Concepts system. *Br J Oral Maxillofac Surg* 2013;**51**:620–4.
30. Burgess M, Bolwer M, Jones R, et al. Improved outcomes after alloplastic TMJ replacement: analysis of a multicenter study from Australia and New Zealand. *J Oral Maxillofac Surg* 2014;**72**:1251–7.